

ANATOMICAL STUDY OF INFERIOR THYROID ARTERY AND THE VARIATION IN THE RELATIONSHIP BETWEEN RECURRENT LARYNGEAL NERVE AND INFERIOR THYROID ARTERY IN SRI LANKAN POPULATION

Romini Niranjana^{*1}, Surangi. G. Yasawardene².

^{*1} Department of Anatomy, Faculty of Medicine, University of Jaffna, Sri Lanka

² Department of Anatomy, Faculty of Medical Sciences, University of Sri Jayewardenepura, Sri Lanka.

ABSTRACT

Introduction: Terminal branches of inferior thyroid artery (ITA) supplies thyroid and parathyroids. Recurrent laryngeal nerve (RLN) is related to ITA at lower pole of thyroid and RLN may lie either posterior, anterior or intermingled with terminal branches of ITA. RLN is a vulnerable structure that gets damaged during thyroid surgeries.

Aim: Present study aims to determine variation in relationship between ITA and RLN, entering pattern of ITA into thyroid and number of terminal branches of ITA in Sri Lankan population.

Materials and methods: A total of 312 sides (Male:204, Female:108) of thyroid together with intact neurovascular structures were selected for study of relationship, entrance pattern and number of terminal branches of ITA. The RLN may lie either posterior (Type A) or anterior (Type B) to ITA or its branches. Sometimes RLN may intermingle with terminal branches of ITA (Type C).

Results: A total sample of 65.2% in male (M) and 60.9% in female (F) were Type A, samples of 10.35%(M) and 22.22%(F) were Type B and 24.5%(M) and 17.59%(F) were type C. Type A was more predominant in left side of both genders and in the right side there are 50% of chances for Type A in both genders. Comparatively Type B was more in female and Type C was more in male. A total of 63.7%(M) and 69.44%(F) ITA entered into middle 1/3rd, 36.27%(M) and 30.55%(F) into lower 1/3rd of the thyroid lobe and entering pattern was more or less similar in both genders. ITA commonly entered thyroid just above junction of middle and lower third of thyroid lobe. ITA divided into two branches in 52.45%(M) and 56.48%(F), three in 44.6%(M) and 41.66%(F) and four in 2.94%(M) and 1.85%(F) of studied samples.

Conclusions: Knowledge of anatomical variation of ITA and RLN is mandatory to avoid injury to RLN in thyroid surgeries. Understanding the entrance pattern and terminal branches of ITA are essential for thyroid and parathyroid surgeries.

KEY WORDS: Inferior thyroid artery, Recurrent laryngeal nerve, Anatomical variations, Thyroid gland, Parathyroid gland.

Corresponding Author: Dr. Romini Niranjana, Department of Anatomy, Faculty of Medicine, University of Jaffna, Sri Lanka. **E-Mail:** rominiranjana@yahoo.com

Access this Article online	Journal Information
Quick Response code  DOI: 10.16965/ijar.2020.113	International Journal of Anatomy and Research ISSN (E) 2321-4287 ISSN (P) 2321-8967 https://www.ijmhr.org/ijar.htm DOI-Prefix: https://dx.doi.org/10.16965/ijar 
	Article Information
	Received: 31 Jan 2020 Peer Review: 01 Feb 2020 Revised: None
	Accepted: 20 Feb 2020 Published (O): 05 Mar 2020 Published (P): 05 Mar 2020

INTRODUCTION

The inferior thyroid artery (ITA) arises from the thyrocervical trunk. It runs upward and crosses

behind the carotid sheath in the carotid triangle. The ITA enters either the lower or middle third of thyroid lobe and divides into two or more

terminal branches [1]. ITA provides branches before it enters into thyroid lobe [2]. ITA supplies the thyroid and parathyroid glands. It is always intimately related to recurrent laryngeal nerve (RLN) near the lower pole of thyroid and RLN may lie either posterior or anterior to main trunk of ITA or its terminal branches. Sometimes RLN may intermingle with the terminal branches of ITA [3, 4]. RLN is the most vulnerable structure that gets damaged during most of the thyroid surgeries [2].

The knowledge of the anatomical variation in the relationship between these two structures is important during the exposure and the mobilization of thyroid gland in the various stages of thyroidectomy [3] and it is a necessary requirement for the safe thyroid surgery.

Toni et al. (2005) analyzed the site of origin and the branching pattern of its terminal branches and stated that above factors might be influenced by ethnic group and gender [4].

The aim of this study is to determine the variation in relationship between ITA and RLN, the entering pattern of ITA into the thyroid gland and the number of terminal branches of ITA in fresh post-mortem samples of Sri Lankan.

MATERIALS AND METHODS

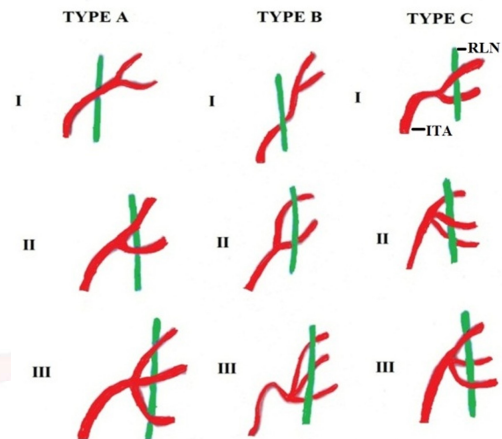
Ethical clearance was obtained from Ethics Review Committee of Faculty of Medical Sciences, University of Sri Jayewardenepura. A total of 312 sides of autopsy samples of thyroid (204 males and 108 females) in which both neurovascular structures intact were used for this study. The samples were obtained along with the trachea from deceased person aged between 18-90 years from the Judicial Medical Office, Colombo South Teaching Hospital.

Dissection was carried out by the routine collar skin incision on anterior surface of the neck. The course of ITA near the thyroid region was carefully observed over the deep fascia. The relationship between RLN and ITA was noted on both sides by looking at their intersection point and it was classified into three basic types which were adapted from Rimi and Boss, 2010. Yasawardene et al., 2000 [3, 5]. RLN which passing posterior to ITA or its branches as type A. RLN which passing anterior to ITA or its branches as type B. RLN which passing between

the terminal branches of ITA as type C (Fig 1).

The samples in which the artery or nerve was accidentally injured during dissection and recurrent laryngeal nerve bifurcate into small branches (extra laryngeal branches) before it entered into larynx were excluded.

Fig .1: Classification of relationship between inferior thyroid artery and recurrent laryngeal nerve.



A total of 312 ITA were used to determine the entrance pattern of ITA into thyroid gland. Length of thyroid gland was measured by using the Vernier Caliper and entering pattern was categorized into three types by partitioning the thyroid lobe into three and those entered into upper third as (U), middle third as (M) and lower third of thyroid lobe as (L) respectively.

Later thyroid gland along with the intact neurovascular structures was dissected from autopsy body, washed with tap water and tagged with a labeled thread with an identification number. The samples were preserved in 10% formal saline and used for further study to determine the number of terminal branches of ITA under the dissecting microscope.

RESULTS

Anatomical relationship: A total of 65.2% of studied samples in male and 60.19 % in female were type A, 10.3% in male and 22.22% in female were type B (Fig 2) and 24.5% in male and 17.59 % in female were type C in Sri Lankan population (Table 1 & 2).

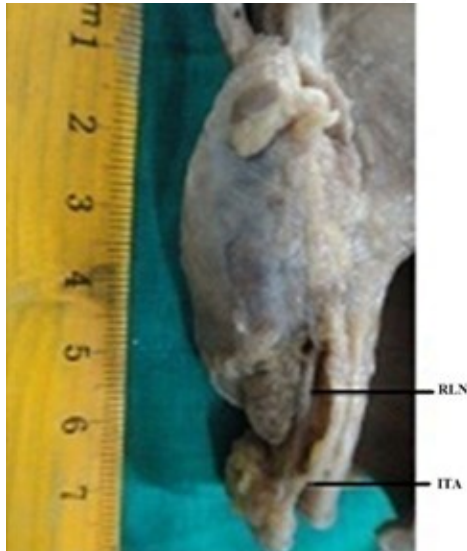Table 1: Anatomical relation between inferior thyroid artery and recurrent laryngeal nerve in male.

Side	Number	Type A	Type B	Type C
Left	106	83	7	16
Right	98	50	14	34
Total	204	133 (65.2%)	21 (10.30%)	50 (24.50%)

Table 2: Anatomical relation between inferior thyroid artery and recurrent laryngeal nerve in female.

Side	Number	Type A	Type B	Type C
Left	51	36	10	5
Right	57	29	14	14
Total	108	65 (60.19%)	24 (22.22%)	19 (17.59%)

Fig. 2: Posterior view of thyroid showing RLN passes anterior to ITA (Type B) Entering pattern.



It was noted that main trunk of ITA entered either into middle 1/3rd or lower 1/3rd of the thyroid lobe. A total of 63.7% of ITA in male and 69.44% in female entered into the posterior aspect of middle 1/3rd of thyroid lobe and 36.27% in male and 30.55% in female entered into lower 1/3rd of thyroid lobe in both genders of Sri Lankan population. Entering pattern is more or less similar in both genders (Table 3 & 4).

Table 3: Entrance of inferior thyroid artery into partitions of thyroid lobe in male.

Side	Number	Middle 1/3 rd	Lower 1/3 rd
Left	106	68	38
Right	98	62	36
Total	204	130(63.72%)	74(36.27%)

Table 4: Entrance of inferior thyroid artery into partitions of thyroid lobe in female.

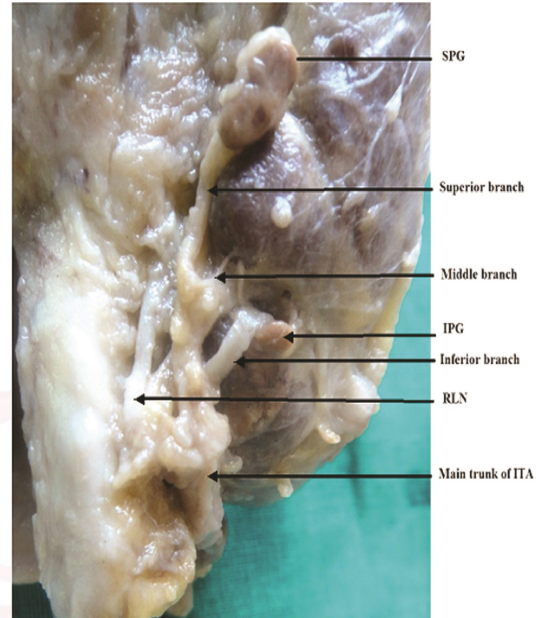
Side	Number	Middle 1/3 rd	Lower 1/3 rd
Left	51	35	16
Right	57	40	17
Total	108	75 (69.44%)	33 (30.55%)

From this study, it was observed ITA commonly enters the middle third of thyroid lobe, just above the junction of middle and lower third of thyroid lobe.

Branching pattern: Out of 204 samples in male,

52.45% samples have two, 44.60% have three (Fig 3) and 2.94% samples have four terminal branches. In female, out of 108 samples, 56.48% have two, 41.66% have three and 1.85% have four terminal branches in Sri Lankan population.

Fig. 3: Main trunk of inferior thyroid artery divides into three terminal branches.



It was observed that by tracing RLN upwards helps in the identification of the main trunk of ITA and its terminal branches. It was noted that some of the parathyroid received its blood supply directly from the terminal branches of ITA (Fig 3).

DISCUSSION

Rimi and Bose, (2010) commented that although there are 28 possible variations of relation between ITA and RLN but for practical purposes only 3 major types were considered to be important [3]. Kulekci *et al.* (2012) had made a detailed classification of relationship [6].

In this present study, it was confirmed that type A was most common in left side of both genders and approximately 50% of chance of Type A in right side of both gender in the Sri Lankan population. Type B was comparatively more in females and Type C was comparatively more in males of Sri Lankan population (Table 1 & 2).

This study was more or less similar to the findings of Idris *et al.*, 2013 and El Karim *et al.*, 2014 in Sudan population [7,8].

The study done by Rimi and Boss (2010) in Bangladesh reported that RLN was most likely

to be located posterior and least likely to be anterior in left side and there were almost equal chances of finding the RLN anterior, posterior or intermingled with the branches of the ITA in right side [3]. Campos *et al.* (2000) observed that type C was predominant in both left and right sides of Brazil population [9].

The knowledge of variation in the relationship is important while placing the ligature in ITA to safe guard RLN in all cases. Usually ligation is placed away from the lower pole in order to safeguard the RLN. It was observed that RLN located between the branches of ITA (type C) was more vulnerable for injury during thyroidec-tomy than other two types.

The extra laryngeal branches were given off by RLN either before or after crossing ITA. Thus terminal division of both ITA and RLN were also interfere the relationship.

Pradeep *et al.* (2012) observed that the bifurca-tion of RLN was more commonly occurs distal to the crossing with ITA [10].

From this study, it was noted that the most of ITA entered into the middle 1/3rd of thyroid lobe and this is similar to the study done by Wood *et al.* (2010) [11].

It was observed that majority of ITA divided ei-ther into 2 or 3 terminal branches very close to the capsule of thyroid gland and the terminal branches run in between false and true capsule of the thyroid lobe.

Superior parathyroid gland (SPG) most commonly located above ITA and inferior parathyroid gland (IPG) lie below ITA on posterolateral aspect of inferior pole of thyroid [11]. ITA was the main arterial supply for both SPG and IPG [12]. ITA provides minimal contribution to thyroid [13].

Identifying RLN more distally near the cricothy-roid joint and follow the RLN to its crossing point with ITA has the less chance of disturbance to the blood supply of IPG [14].

Ligation of terminal branches close to thyroid capsule and away from RLN was another measure for an expert thyroid surgery [15].

CONCLUSION

Anatomical knowledge in the variation of relationship between ITA and RLN is mandatory for avoiding the unwanted injury to RLN in the

neck operation. The deep understanding of entrance pattern and terminal branches of ITA is very essential for thyroid and parathyroid surgeries.

ABBREVIATIONS

ITA - Inferior thyroid artery

RLN - Recurrent laryngeal nerve

SPG- Superior parathyroid gland

IPG – Inferior parathyroid gland

M- Male

F- Female

ACKNOWLEDGEMENTS

I acknowledge the financial support through grants of ASP/06/RE/MED/2012/16 of University of Sri Jayewardenepura to carry out this research.

Conflicts of Interests: None

REFERENCES

- [1]. Theodoros M. Bilateral aberrant origin of inferior thyroid artery from common carotid artery. Anatomical variation. *Sur Radio Anat*, 2013;36(3): 295-297.
- [2]. Mohebbati A, Shaha, A.R. Anatomy of thyroid and parathyroid glands and neurovascular relations. Head and neck service, Memorial Sloan Kettering Cancer Center, New York, New York Clinical Anatomy. 2012;25:19–31.
- [3]. Rimi K.R, Bose B.K. Position of terminal branches of inferior thyroid arteries in relation to recurrent laryngeal nerve. *Dinajpur Med Col J*. 2010;3(2) :47-54.
- [4]. Toni R, Casa C.D, Castorina S, Roti E, Ceda G, Valenti G. A. meta- analysis of inferior thyroid artery variations in different human ethnic groups and their clinical implications. *Ann Anat*. 2005;187(4):371-85.
- [5]. Yasawardene S.G, Wijeratne T.K. Relationship between the recurrent laryngeal nerve and inferior thyroid artery in Sri Lankans. *Proceedings of annual sessions of Sri Lanka association for advancement of science*. 2000;56:127-133.
- [6]. Kulekci M, Batioglu-Karaaltin A, Saatci O, Uzun I. Relationship between the branches of the recurrent laryngeal nerve and the inferior thyroid artery. Turkey. *Ann Otol Rhinol Laryngol*. 2012;121(10):650-656.
- [7]. Idris S, Ali Q.M, Hamza A.A. Incidence and variations in the relationship between the recurrent laryngeal nerves to the inferior thyroid arteries in Sudanese subjects. *Scholar's journal of applied medical sciences (SJAMS)*, 2013;1(5):575-580.
- [8]. El Karim M.K.E.A, Nurein M.A.S, Hassan M.A. Thyroid gland morphology with special considerations of the recurrent laryngeal nerves variations. *Khartoum Medical Journal*, 2014;07(03):1040-1042.

- [9]. Campos B. A, Henriques P.R.F. Relationship between the recurrent laryngeal nerve and inferior thyroid artery: A study in corpses. Rev. Hos. Clin. Fac. Medicine. S. Paulo, 2000;55(6):195-200.
- [10]. Pradeep P.V, Jayashree B, Harshita S. S. A closer look at laryngeal nerves during thyroid surgery: A descriptive study of 584 nerves, Clinical study. Anatomy Research International, 2012;2012:1-6.
- [11]. Wood W. C, Skandalakis E, Staley C. A. Anatomic Basis of Tumor Surgery, Springer-Verlag Berlin Heidelberg; 2nd edition, edited by Charles Stanley.2010:80-82.
- [12]. Ghervan C. Thyroid and parathyroid ultra sound. Beginner corner. Medical Ultrasonography. 2011;13(1): 80-84.
- [13]. Kapre and Madan. Preservation of parathyroid in thyroid surgery. World Articles in Ear, Nose and Throat, www.waent.org 2009;2(1):1-5.
- [14]. Maisie L. Shindo, James C. Wu, Eunice E. Park, MPH. Surgical Anatomy of recurrent laryngeal (Revisited) Review article. Otolaryngology – Head and neck surgery. 2005;133(4):514–519.
- [15]. Bhargav PR. Salient anatomical landmarks of thyroid and their practical significance in thyroid surgery: a pictorial review of thyroid surgical anatomy (revisited). Indian Journal of Surgery. 2014 Jun 1;76(3):207-11.

How to cite this article:

Romini Niranjana, Surangi. G. Yasawardene. ANATOMICAL STUDY OF INFERIOR THYROID ARTERY AND THE VARIATION IN THE RELATIONSHIP BETWEEN RECURRENT LARYNGEAL NERVE AND INFERIOR THYROID ARTERY IN SRI LANKAN POPULATION. Int J Anat Res 2020;8(1.3):7403-7407. DOI: 10.16965/ijar.2020.113